

ADVANCES IN HYDROSURGERY TECHNIQUES FOR WOUND DEBRIDEMENT"

Dr. Ricardo J. Bolaños Díaz¹, Dr. Mariana E. González Vargas²

Article Info

Keywords: Wound bed preparation, Debridement, Hydrosurgery, Healing barriers, Venturi effect

Abstract

Effective wound bed preparation is essential to facilitate subsequent reepithelization by eliminating barriers that impede the healing process. These barriers include necrotic tissues, bacterial colonization, moisture imbalances, and compromised wound margins. Therefore, achieving optimal ulcer bed debridement is critical in addressing these challenges. Traditional methods of wound bed preparation, such as scalpel excision, have been the gold standard; however, emerging techniques offer enhanced efficiency and safety. These include autolytic, enzymatic, mechanical (negative pressure), biological (larvae), and hydrosurgery-based approaches. Despite the promise of these innovative technologies, further research with robust experimental designs is needed to build upon initial observations.

In this context, hydrosurgery systems, like Versajet®, have been in use for over two decades. They operate on the Venturi effect principle, with pressurized saline or sterile water passing through a nozzle in a handheld device. This pressurization generates a high-speed, cutting fluid (tangential hydrojet) and creates localized vacuum forces, effectively removing non-viable tissue by suction and transporting it to an external collection system. This review aims to explore the potential of hydrosurgery in wound bed preparation and its contribution to improved clinical outcomes.

Introduction

The wound bed should be optimized to allow adequate subsequent reepithelization, which implies removing all barriers that prevent or hinder it. These barriers include necrotic tissues, bacterial load, moisture imbalance and

¹ Universidad Nacional Federico Villarreal, Escuela de Salud Pública, Lima, Peru

² Organización Médica para el Desarrollo de la Salud - ODDS PERU, Lima, Peru

deterioration of wound margins. Therefore, the optimal debridement of the ulcerated bed is crucial for the control of these four barriers.¹

Although the standard procedure for the preparation of the wound bed has been ---and continues to be--- debridement by scalpel excision, new techniques have emerged that involve greater efficiency and safety, such as autolytic, enzymatic debridement, mechanic with negative pressure, biological with larvae and hydrosurgery. However, the evidence with these new technologies is still scarce and needs better experimental designs to consolidate previous observations.²

In that sense, the hydrosurgery system (Versajet®) has been applied for more than 20 years and exerts its action based on the Venturi effect principle (special case of Bernoulli's principle). A tangential flow of saline or sterile water flows by pressurization (through a console) to a nozzle located in a handpiece (connected to the console by means of a flexible hose).

This pressurization through the narrow nozzle generates a thin and cutting fluid (tangential hydrojet) that is propelled at high speed, also generating a localized vacuum effect due to a decrease in the surrounding pressure (Bernoulli principle). The excision is mainly exerted on the non-viable tissue whose debridement allows its suction and elimination towards an external collector.³

The tangential hydrojet system allows the elimination of necrotic and non-viable tissue conveniently preserving the maximum underlying dermal layer, with minimal bleeding. Its Venturi effect reduces the risk of contamination of the surrounding environment and reduces the bacterial load in the wound bed without contamination of the underlying dermal layers. It also allows a more precise debridement in areas of difficult debridement with a scalpel.^{4, 5}

Different SRs have been published to compare the technique of tangential hydrojet with conventional debridement with a scalpel each with a defined search strategy according to its primary objective(s). The emergence of new reports has allowed more studies to be included for SRs and it is important to summarize those SRs that meet sufficient quality criteria. The objective was to determine the effectiveness and safety regarding the use of hydrosurgery in the debridement of acute or chronic wounds, including burns.

Method

Population: adults or children with acute or chronic wounds (including burns). Intervention: hydrosurgery or Versajet® system. Comparator: conventional debridement. Results: effectiveness and safety.

The search was carried out in the PUBMED, SCOPUS, OVID and EMBASE databases. The following search strategy was applied:

(versajet OR tangential hydrosurgery OR hydrosurgery system OR hydrosurgery debridement OR hydrodebridement OR hydros scalpels OR "water jet surgery") **AND** (wound* OR burn* OR wound healing)

LIMITS: Systematic reviews in English or Spanish.

Selection of SRs

The selection of articles was developed in two steps: First, the articles identified by the search strategy were filtered by reading titles and abstracts that suggested content relevant to our objective. Second, the full-text articles selected in the first step were accessed. After its complete reading, it was verified that these articles met the selection criteria established for this review.

Data extraction and management

RCTs and observational studies included in qualitative/quantitative analyses were selected from each SR. The references list of each SR and included study were reviewed in order to identify relevant primary studies that had not been filtered by the search strategy.

Assessment of the methodological quality of SRs

Only SRs that met 80% of the AMSTAR (Assessment of Multiple Systematic Reviews) criteria were selected.⁶

Results

Five SRs were selected according to the AMSTAR criteria. Two SRs were excluded (**Figure 1**).^{1,2} **Table 1** shows the comparison of the five SRs selected for this overview.

Figure 1: Study flow diagram

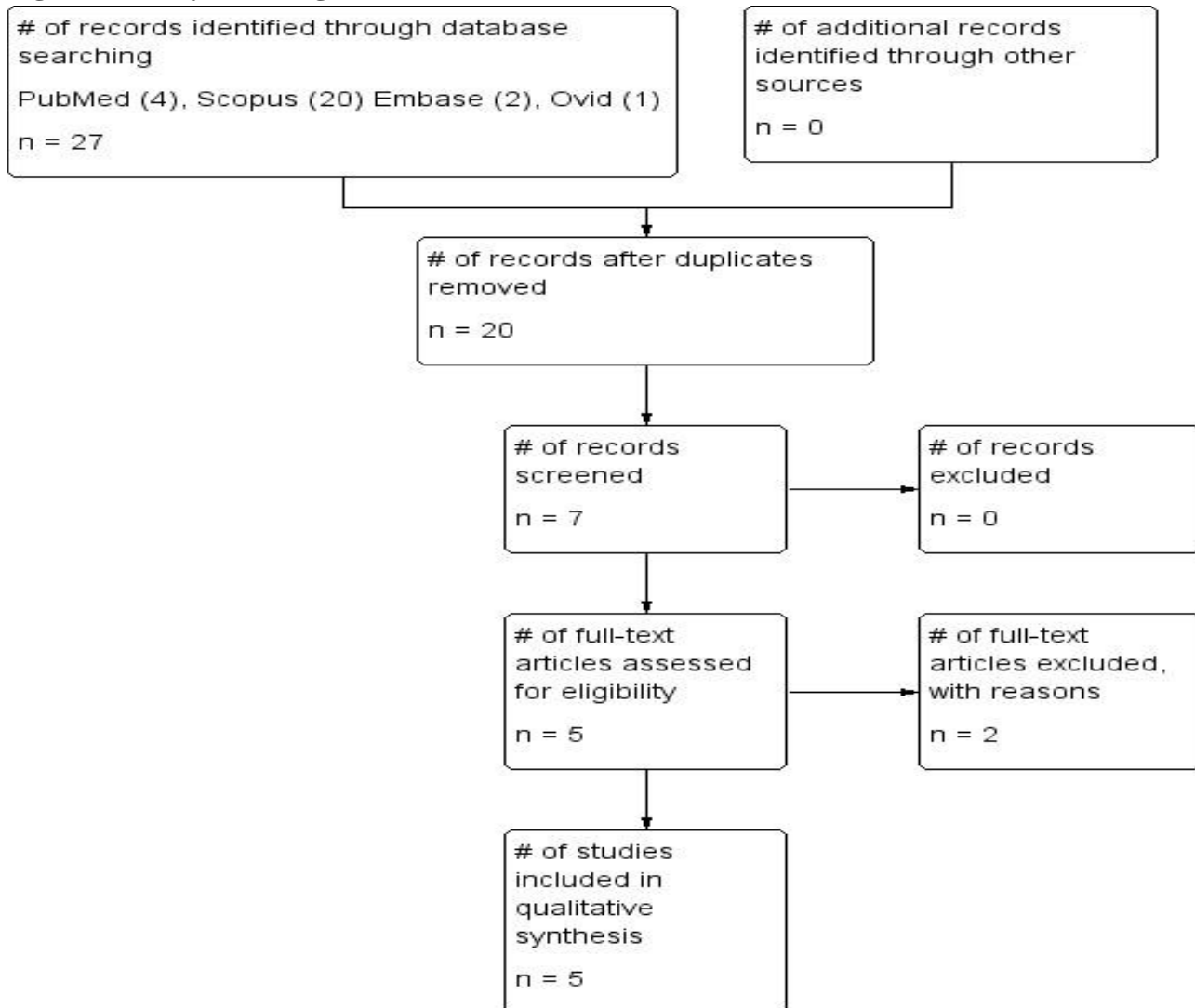


Table 1: Characteristics of the selected SRs

Characteristic	Kakagia 2017	Edmondson 2018	Bekara 2018	Kwa 2019	Elraiyah 2016
Objective	Analyze evidence of efficacy, safety and CE	Analyze the evidence with various debridement techniques to determine if it is time to stop considering the gold standard for scalpel excision	Compare 3 technologies for wound management: hydrosurgery (Versajet® system), ultrasound (MIST® device) and radiofrequency ablation (Coblation®)	Review the evidence since 1990 about surgical and nonsurgical debridement techniques	Review the evidence regarding debridement techniques used in the management of diabetic foot ulcers
Wound type	Burn wounds	Burn wounds	Any ulcerated wound	Burn wounds	Diabetic foot ulcers
Selected RCTs	Gravante 2007 Granick 2007 Hyland 2015	Gravante 2007 Hyland 2015 Rosenberg 2014	Caputo 2008 Liu 2015	Gravante 2007 Hyland 2015	Caputo 2008
Selected observational studies	Cubison 2006 Duteille 2012 Irkoren 2014 Klein 2005 Matsumura 2012 Rennekampff 2006 Tenenhaus 2007 Gurunluoglu 2007	Aniboletti 2011 (*) Duteille 2012 Kawecky 2015 Klein 2005 Matsumura 2012 Tenenhaus 2007	Gurunluoglu 2007 Dillon 2010 Vanwijck 2010 Fracalvieri 2011 Sivrioglu 2014	Tenenhaus 2007 Kawecky 2015 Duteille 2012 Rennekampff 2006 Yang 2007 Cubison 2006	None
Comparator in the RCT	Scalpel debridement Pulsed wash	Scalpel debridement (**)	Scalpel debridement	Scalpel debridement	Scalpel debridement
Outcomes	Ease for debridement Number of interventions Operating time Reepithelization time Post-surgery pain Adverse events Contracture rate Dermal preservation Bacterial load	Operating time Post-surgery pain Complete reepithelization Contractures at 6 months	Operating time Reepithelization time Costs Stable wound healing Bacterial load	Complete reepithelization time Complete debridement time	Debridement time Reepithelization time

	Infection rate Successful grafts Cost <i>per</i> procedure				
Conclusion	Tangential hydrojet system allows immediate skin grafting with good results. It probably reduces hospital stay. It is safe and costeffective for USA and UK	Tangential hydrojet system shows greater preservation of the dermis and, potentially, with better healing in the long term. Similar to the comparator in the other aspects. Suggests changing the paradigm of considering scalpel debridement as a standard.	Level B recommendation for RCT with a tangential hydrojet system. Ultrasound technique shows a significant reduction in reepithelization time and a shorter surgery time.	Better results regarding the need for grafts and healing quality.	The tangential hydrojet system significantly reduced the debridement time but without major difference in the reepithelization time of the ulcer (conclusion extrapolated to the sub-group of diabetic ulcer)

The SR of Kakagia *et al*⁷ aimed to explore the evidence regarding the efficacy, safety and cost-effectiveness of hydrosurgery (Versajet®) in the management of burn wounds. It rendered a total of 20 articles, of which 3 were RCTs.^{8,10} Of these, two RCTs exclusively included burn injuries^{8,9} and 1 RCT included acute injuries in general (including burns).¹⁰

Edmondson *et al*¹¹ reviewed the evidence accumulated with various burn wound debridement techniques to determine if it is time to stop considering the gold standard for scalpel excision. His SR yielded 18 studies, of which 3 were RCTs^{8,9,12} that compared the tangential hydrojet system with other technologies used as standard in the study center. Bekara *et al*¹³ compared the evidence regarding three wound debridement technologies: hydrosurgery, ultrasound and radiofrequency. The analyzed outcomes were the number of interventions needed with each technique, intervention-time, time for healing, bacterial load, blood loss and cost-efficiency. The search strategy yielded 7 studies for the hydrosurgery technique (255 patients), of which only 2 were RCTs.^{14,15}

The SR of Kwa *et al*¹⁶ was proposed to compare the efficiency and safety of all surgical and non-surgical techniques (used since 1990) for burn wound debridement. The search strategy yielded 27 articles for data extraction and analysis. Eight studies included the technique of hydrosurgery (Versajet®), of which two were

RCTs.^{8,9} Elraiayah *et al*¹⁷ reviewed the evidence regarding the debridement techniques used in the management of diabetic foot ulcers. His SR selected one single RCT with the technique of hydrosurgery.¹⁴

The SR of Kakagia *et al*⁷ included three RCTs⁸⁻¹⁰ and other observational studies. In general, at the level of RCTs, the use of hydrosurgery showed greater precision than conventional manual debridement, especially in anatomical areas of difficult contours; however, the healing quality and infection rates were similar. One RCT¹⁰ concluded that the use of hydrosurgery for wound debridement achieved a significant reduction in the average number of surgical interventions, although this conclusion could be subject to bias due to the possible heterogeneity of the groups compared.

At the level of observational studies,¹⁸⁻²⁵ the quality of the evidence is low to moderate and the conclusions of some of them are not sufficiently supported by the results report.²³ Effectiveness of debridement is mainly supported by the evolution of healing and graft success, and not by the biopsy study. In other studies, the subsequent evolution of the wound may well have been influenced by the use of biological dressings in terms of healing quality, reepithelization time and bacteriology.^{19,23,21,18,24} However, other studies reinforce the greater accuracy of hydrodebridement and its ability to preserve the dermis.²² Additionally, three studies suggested new techniques of use for hydrodebridement. The first, using 0.9% hydrogen peroxide instead of physiological serum;²⁰ the second, using the tangential hydrojet for the management of scar tissue overgranulation;¹⁸ and the third, in the removal of flanges and adhesions of burn bed margins, complementing the debridement with a scalpel or electrocautery.²⁶

On the safety of the hydrodebridement technique, Kakagia *et al* reviewed the evidence regarding contamination of the surrounding environment by aerosolization of the biological residue debrided by the tangential hydrojet. This contamination has been observed in previous evidence.^{27,28} In this regard, several observations determine that the risk of contamination is minimized by the suction effect of the tangential hydrojet technology (Venturi effect); however, such conclusions have not been sufficiently supported by microbiological methods.^{4,10,18}

Regarding the economic analysis, the Kakagia's SR refers to a pair of previous studies that evaluated some aspects of cost-effectiveness.^{9,10} Hyland *et al*⁹ reported that the tangential hydrojet system (Versajet®) had an estimated cost of £ 6000 and £ 220-240 for the equipment and handpiece, respectively. Although some factors may well compensate for the high cost, such as a reduction in hospital stay and the number of surgical interventions, there is still a need for more evidence from RCTs to define well the magnitude of cost-effectiveness. For its part, Granick *et al*¹⁰ estimated a significant reduction in the number of surgical interventions with the use of the tangential hydrojet system (1.9 vs 1.2), calculating a net cost saving of US \$ 1900 *per* patient. However, with respect to the USA and the UK, such estimates may not be extrapolated to other realities with large differences in their health systems. The SR of Edmondson *et al*¹¹ analyzes the evidence regarding three debridement technologies used in the management of burn wounds: scalpel, hydrosurgery and enzymatic. It included three RCTs^{9,10,12} regarding the tangential hydrojet system, and it also included observational studies.^{19,21,22,24,29,30} The authors concluded that the scalpel debridement method should be considered as a standard reference technology for the management of burn wounds and other technologies ---such as debridement by hydrosurgery or enzymatic debridement--- have accumulated enough evidence to position themselves as technologies with better performance regarding the preservation of the dermis, reduction of healing time and the need for grafts, in addition to providing better healing quality.

The SR of Bekara *et al*¹³ compared three technologies for wound management: hydrosurgery (Versajet® system), ultrasound (MIST® device) and plasma-mediated radiofrequency ablation (Coblation®). Regarding

hydrosurgery, seven studies were analyzed,^{14,15,25,31,32,33,34} within which two RCTs^{14,15} and several case reports^{31,32,34} were included. 86.3% of patients (220/255) needed one single hydrosurgical procedure. The authors of this SR report that the benefit of the tangential hydrojet system, in terms of reduction of bacterial load, is well recognized despite the fact that there are reports that failed to demonstrate this benefit objectively.¹⁵ Similarly, they recommend limiting its use in hemorrhagic wounds because the Venturi system can negatively affect the local coagulation process (authors' own experience).

Kwa *et al*¹⁶ developed a SR whose objective was to provide a complete review (since 1990) of surgical and nonsurgical debridement techniques regarding efficiency and safety in burned patients. He analyzed 27 articles for the following debridement techniques: 1) conventional scalpel excision, 2) hydrosurgery, 3) enzymatic debridement, and 4) ultrasound shock waves. The primary results defined in the protocol were time to achieve complete healing and time to achieve complete debridement.

Regarding the hydrosurgery technique (tangential hydrojet), the SR of Kwa *et al* selected two RCTs^{8,9} and six observational studies.^{18,19,23,24,30,35} With conventional debridement as a comparator (scalpel excision), one RCT reported a complete healing time of 11 (SD=2) and 13 (SD=2) days for tangential and scalpel hydrojet debridement, respectively.⁸ Another RCT reported for the same outcome 32.6 (18-64) and 30.4 (16-70) days, respectively.⁹ Additionally, 3/6 observational studies reported a complete healing time between 11.8 and 13.4 days.^{18,19,24} Additionally, a comparative RCT reported a time to achieve complete debridement of 9 (SD=3) and 10 (SD=3) days with the tangential and scalpel hydrojet technique, respectively.⁸ Regarding this last outcome, 4/6 observational studies reported a time between 4.4 and 23 days.^{19,23,30,35}

Elraiayah *et al*¹⁷ reported the efficacy of several debridement techniques for diabetic foot ulcers, and found no significant difference between the techniques compared. The authors warn of the poor quality of the studies analyzed and suggest basing the use of one technique or another in relation to the surgeon's experience, patient preferences, clinical context and costs. For the tangential hydrojet technique, this SR selected one single RCT¹⁴ which included in its cohort 22 patients diagnosed with diabetic ulcer (diabetic foot). In its global cohort (including all types of ulcers), Caputo *et al*¹⁴ concluded that the tangential hydrojet system significantly reduced the debridement time but without major difference in the reepithelization time of the ulcer with respect to conventional debridement with scalpel. He did not report results in the diabetic foot subgroup.

Discussion

In burn wounds, the hydrosurgery system (tangential hydrojet) seems to decrease the number of surgical interventions (debridements) as well as favoring a greater preservation of the underlying dermis and precision of debridement at the level of difficult contours. However, the evidence should be considered of low consistency due to the scarce of RCTs, the low statistical power and the moderate risk of bias in study designs. We consider a low risk of bias in this overview of SRs because recommendations about selection and peer-review analyses were followed.

The studies support the applicability of the tangential hydrojet system in burn wounds for optimal debridement. Although the risk of contamination of the environment close to the procedure seems negligible due to the Venturi effect of suction of debrided tissues it will be important to generate experimental evidence with sufficient microbiological methods to support the absence of cross contamination.

For its part, the National Institute for Health and Care Excellence (NICE)³⁶ reported its technology assessment according to the analysis of an external evaluation institution (Medtech). This independent SR selected 6 RCTs,^{8,14,15,29,37,38} of which 3 were performed in burn wounds and 3 in chronic wounds. Likewise, it incorporated

the analysis of 3 comparative observational studies.^{10,39,40} The SR concluded that the tangential hydrojet system takes the same time for wound debridement as comparators.

However, the authors recognize that at the time of the SR, a large part of the included studies (4 RCTs and 1 observational trial) were *Abstracts* or *Posters* presented at scientific meetings,^{15,29,37,38,40} so they warn that the conclusions are weak because such presentations do not always correlate well with the final results published after a peer review. It is important to note that the NICE 2014 analysis has not yet been updated and suffers from the lack of selection of studies analyzed in other SRs^{8,9,12,14} and from the published versions of some previous abstracts/posters.^{15,38,39}

For the tangential hydrojet technique, the SR of Elraiya *et al* selected one single RCT¹⁴ which included in its cohort 22 patients diagnosed with diabetic ulcer (diabetic foot). Although such RCT reported the results for its total cohort (which included ulcers of different etiology) the extrapolation is valid for the diabetic ulcer subgroup, which represented 53.6% of its total cohort. In reinforcement of this conclusion, Hong *et al*⁴¹ in a non-comparative pilot trial of 15 patients with diabetic foot ulcer observed satisfactory healing with tangential hydrojet debridement for their total cases.

Regarding trauma injuries, Oosthuizen *et al*⁴² developed one RCT in tibial fracture open wounds (grade III-A and II-B of the Gustilo & Anderson classification). The objective was to compare the tangential hydrojet system with conventional surgery. The primary outcome was the total number of debridements until the wound was closed. Forty patients were recruited, of which 16 received tangential hydrosurgery and 24 received standard surgical debridement. The authors observed significant evidence to conclude that patients treated with the Versajet® system required fewer debridement procedures (standard surgery/Versajet® ratio = 1.747 p<0.001). On the other hand, the median time to wound closure was 3 days (IC95: 3-5 days) for the Versajet® system and 5 days (IC95: 4-8 days) for conventional surgery ($p = 0.275$).

Although experimental level studies (RCTs) are still scarce, the cumulative observational data (for burn wounds) provides epidemiological consistency to assume greater precision in debridement with better wound evolution. It is worth noting that some trials of this type (observational or quasi-experimental) have not been incorporated into any of the 5 selected SRs despite meeting good quality criteria. Such is the case of the retrospective study by Legemate *et al*,⁴³ who reported the results of a large cohort of 2,113 burn patients, where 23.9% were treated with hydrosurgical debridement (Versajet®), 47.7% with conventional scalpel debridement or a combination of both techniques (28.3%). The authors observed some independent predictors of good response with the Versajet® system such as: young age, ulceration, higher percentage of burned area, head and/or neck burns, arm burns and irregular contour burns. Currently, this team of researchers is conducting a comparative RCT (<http://www.trialregister.nl>, NTR6232) between hydrosurgery and scalpel debridement to compare the quality of healing in burn patients.

Although the evidence is more numerous in the case of burn injuries, the results observed for other types of injury are similar for the hydrosurgery system; therefore, extrapolation of such results is plausible. However, the quality of evidence (low-moderate) makes it necessary to accumulate more studies with experimental design to consolidate these preliminary conclusions.

Conclusion

The use of hydrosurgery for the debridement of a wound could be associated with a reduction in the average number of surgical interventions and hospital stay, which would compensate in the medium term for high costs *per* patient (associated with the use of equipment and handpieces). However, this conclusion could be subject to bias due to the heterogeneity of the studies.

Further studies with experimental design and greater statistical power are necessary to consolidate the results of this review.

Acknowledgments

To Vanessa Abanto-Bernal B.Lib.Sc, for her valuable help in bibliographic search strategies.

Authors' contribution

Rafael Bolaños-Díaz and Frida Paredes-Alfaro were responsible for the selection of studies, data extraction/analyses and writing of the full-text of the manuscript. All financing was assumed by the authors.

Declaration of Conflicts

Rafael Bolaños-Díaz has provided scientific advice on pharmacoeconomics issues to different pharmaceutical companies.

Frida Paredes-Alfaro declare no conflict of interest.

References

- Hoppe I, Granick M. Debridement of chronic wounds: A qualitative systematic review of randomized controlled trials. *Clin Plastic Surg* 2012; 39: 221–228. [DOI: [10.1016/j.cps.2012.04.001](https://doi.org/10.1016/j.cps.2012.04.001)]
- Madhok BM, Vowden K, Vowden P. New techniques for wound debridement. *Int Wound J* 2013.
- Sainsbury D. Evaluation of the quality and cost-effectiveness of Versajet® hydrosurgery. *Int Wound J* 2009; 6: 24-29. [DOI: [10.1111/j.1742-481X.2008.00560.x](https://doi.org/10.1111/j.1742-481X.2008.00560.x)]
- Kimble RM, Mott J, Joethy J. Versajet hydrosurgery system for the debridement of paediatric burns. *Burns* 2008; 34: 297-298. [DOI: [10.1016/j.burns.2007.08.018](https://doi.org/10.1016/j.burns.2007.08.018)]
- Pascone PM, Papa G, Ranieri A. Use of a novel hydrosurgery device in surgical debridement of difficult-to-heal wounds. *Wounds* 2008; 20: 139-146. [PMID: [25942415](https://pubmed.ncbi.nlm.nih.gov/25942415/)]
- Shea B, Grimshaw J, Wells G, Boers M, Andersson N, *et al.* Development of AMSTAR: a measurement tool to assess the methodological quality of systematic reviews. *BMC Medical Research Methodology* 2007; 7(10). [DOI: [10.1186/1471-2288-7-10](https://doi.org/10.1186/1471-2288-7-10)]
- Kakagia D, Karadimas E. The efficacy of Versajet™ hydrosurgery system in burn surgery. A systematic review. *J Burn Care Res* 2018, Issue 39(2).
- Gravante G, Delogu D, Esposito G, Montone A. Versajethydrosurgery versus classic escharectomy for burn debridement: A prospective randomized trial. *J Burn Care Res* 2007; 28(5): 720-724. [DOI: [10.1097/BCR.0B013E318148C9BD](https://doi.org/10.1097/BCR.0B013E318148C9BD)]
- Hyland E, D'Cruz R, Menon S, Chan Q, Harvey J. Prospective, randomised controlled trial comparing Versajet™ hydrosurgery and conventional debridement of partial thickness paediatric burns. *Burns* 2015; 41(4): 700-707. [DOI: [10.1016/j.burns.2015.02.001](https://doi.org/10.1016/j.burns.2015.02.001)]

- Granick M, Tenenhaus M, Knox K, Ulm J. Comparison of wound irrigation and tangential hydrodissection in bacterial clearance of contaminated wounds: Results of a randomized, controlled clinical study. *Ostomy Wound Management* 2007; 53(4): 64–72. [PMID: 17449917]
- Edmondson S-J, Jumabhoy IA, Murray A. Time to start putting down the knife: A systematic review of burns excision tools of randomised and non-randomised trials. *Burns* 2018, Issue 44(7).
- Rosenberg L, Krieger Y, Bogdanov-Berezovski A, Silberstein E, Shoham Y, Singer AJ. A novel rapid and selective enzymatic debridement agent for burn wound management: A multicenter ECA. *Burns* 2014; 40: 466-474. [DOI: 10.1016/j.burns.2013.08.013]
- Bekara F, Vitse J, Fluieraru S, Masson R, De Runz A. New techniques for wound management: A systematic review of their role in the management of chronic wounds. *Cochrane Database of Systematic Reviews* 2018, Issue 45(2). 14) Caputo WJ, Beggs DJ, DeFede JL, *et al.* A prospective randomized controlled clinical trial comparing hydrosurgery debridement with conventional surgical debridement in lower extremity ulcers. *Int Wound J* 2008; 5: 288-294. [DOI: 10.1111/j.1742-481X.2007.00490.x]
- Liu J, Ko JH, Secretov E, Huang E, Chukwu C, West J, Galiano RD. Comparing the hydrosurgery system to conventional debridement techniques for the treatment of delayed healing wounds: a prospective, randomised clinical trial to investigate clinical efficacy and cost-effectiveness. *Int Wound J* 2015; 12: 456-461. [DOI: 10.1111/iwj.12137] 16) Kwa K, Goei H, Breederveld R, Middelkoop E, van der Vlies C, van Baar M. A systematic review on surgical and non-surgical debridement techniques of burn wounds. *Journal of Plastic, Reconstructive & Aesthetic Surgery* 2019; 72(11): 1752-1762. [DOI: 10.1016/j.bjps.2019.07.006]
- Elraiyah T, Domecq JP, Prutsky G, Tsapas A, Nabhan M, *et al.* A systematic review and meta-analysis of debridement methods for chronic diabetic foot ulcers. *J Vasc Surg* 2016; 63: 37s-45s. DOI: 10.1016/j.jvs.2015.10.002]
- Cubison TC, Pape SA, Jeffery SL. Dermal preservation using the Versajet hydrosurgery system for debridement of paediatric burns. *Burns* 2006; 32: 714-720. [DOI: 10.1016/j.burns.2006.01.023]
- Duteille F, Perrot P. Management of 2nd-degree facial burns using the Versajet® hydrosurgery system and xenograft: A prospective evaluation of 20 cases. *Burns* 2012; 38: 724-729. [DOI: 10.1016/j.burns.2011.12.008]
- Irkoren S, Sivrioglu N. A hydrosurgery system (Versajet) with and without hydrogen peroxide solutions for the debridement of subacute and chronic wounds: A comparative study with hydrodebridement. *Adv Skin Wound Care* 2014; 27: 127-131. [DOI: 10.1097/01.ASW.0000443898.56886.66]
- Klein MB, Hunter S, Heimbach DM, *et al.* The Versajet water dissector: a new tool for tangential excision. *J Burn Care Rehabil* 2005; 26: 483-487. [DOI: 10.1097/01.bcr.0000185398.13095.c5]

- Matsumura H, Nozaki M, Watanabe K, *et al.* The estimation of tissue loss during tangential hydrosurgical debridement. *Ann Plast Surg* 2012; 69: 521-525. [DOI: [10.1097/SAP.0b013e31826d2961](https://doi.org/10.1097/SAP.0b013e31826d2961)]
- Rennekampff HO, Schaller HE, Wisser D, Tenenhaus M. Debridement of burn wounds with a water jet surgical tool. *Burns* 2006; 32: 64-69. [DOI: [10.1016/j.burns.2005.07.010](https://doi.org/10.1016/j.burns.2005.07.010)]
- Tenenhaus M, Bhavsar D, Rennekampff HO. Treatment of deep partial thickness and indeterminate depth facial burn wounds with water-jet debridement and a biosynthetic dressing. *Injury* 2007; 38(suppl 5): s39-s45. [DOI: [10.1016/j.injury.2007.10.039](https://doi.org/10.1016/j.injury.2007.10.039)]
- Gurunluoglu R. Experiences with water jet hydrosurgery system in wound debridement. *World J Emerg Surg* 2007; 2: 10. [DOI: [10.1186/1749-7922-2-10](https://doi.org/10.1186/1749-7922-2-10)]
- Slocombe PD, Simons MA, Kimble RM. A modification of the Hynes procedure—a surgical innovation in the treatment of mature hypertrophic scars in children. *Burns* 2011; 37: 1265-1267. [DOI: [10.1016/j.burns.2011.04.012](https://doi.org/10.1016/j.burns.2011.04.012)]
- Bowling FL, Stickings DS, Edwards-Jones V, Armstrong DG, Boulton AJ. Hydrodebridement of wounds: effectiveness in reducing wound bacterial contamination and potential for air bacterial contamination. *J Foot Ankle Res* 2009; 8: 2-13. [DOI: [10.1186/1757-1146-2-13](https://doi.org/10.1186/1757-1146-2-13)]
- Sönnergren HH, Polesie S, Strömbeck L, Aldenborg F, Johansson BR, Faergemann J. Bacteria aerosol spread and wound bacteria reduction with different methods for wound debridement in an animal model. *Acta DermVenereol* 2015; 95: 272-277. [DOI: [10.2340/00015555-1944](https://doi.org/10.2340/00015555-1944)]
- Anniboletti T, Palombo M, Fasciani L *et al.* The use of Versajet hydrosurgery: 5 year experience. *Burns*: 37S: S19 2011; Suppl 37: s19 (Abstract O27.6).
- Kawecki M, Mikus-Zagorska K, Glik J, Nowak M. The efficiency of burn wounds debridement with use of hydrosurgery--our experiences. *Pol Przegl Chir* 2015; 87(1): 1-5. [DOI: [10.1515/pjs-2015-0010](https://doi.org/10.1515/pjs-2015-0010)]
- Dillon CK, Lloyd MS, Dzeiwulski P. Accurate debridement of toxic epidermal necrolysis using Versajet®. *Burns* 2010; 36: 581-584. [DOI: [10.1016/j.burns.2008.12.011](https://doi.org/10.1016/j.burns.2008.12.011)]
- Vanwijck R, Kaba L, Boland S, *et al.* Immediate skin grafting of sub-acute and chronic wounds debrided by hydrosurgery. *J Plast Reconstr Aesthet Surg* 2010; 63: 544-549. [DOI: [10.1016/j.bjps.2008.11.097](https://doi.org/10.1016/j.bjps.2008.11.097)]
- Fracalvieri M, Serra R, Ruka E, *et al.* Surgical debridement with VERSAJET: an analysis of bacteria load of the wound bed pre- and post-treatment and skin graft taken. A preliminary pilot study. *Int Wound J* 2011; 8: 155-161. [DOI: [10.1111/j.1742-481X.2010.00762.x](https://doi.org/10.1111/j.1742-481X.2010.00762.x)]
- Sivrioglu N, Irkoren S. Versajet hydrosurgery system in the debridement of skin necrosis after Ca gluconate extravasation: report of 9 infantile cases. *Acta Orthop Traumatol Turc* 2014; 48: 6-9. [DOI: [10.3944/AOTT.2014.2941](https://doi.org/10.3944/AOTT.2014.2941)]

- Yang JY, Hwuang JY, Chuang SS. Clinical experience in using the water jet in burn wound debridement. *Ann Burns Fire Disasters* 2007; 20: 72-77. [DOI: [10.1016/j.bjps.2019.07.006](https://doi.org/10.1016/j.bjps.2019.07.006)]
- National Institute for Health and Care Excellence (NICE), UK. The Versajet II hydrosurgery system for surgical debridement of acute and chronic wounds and burns. <http://nice.org.uk/guidance/mib1> February 2014
- Esposito G, Anniboletti T, Palombo M *et al.* Versajet hydrosurgery: our experience in adults and paediatric patients. *Burns* 2009; 35s: s23. [DOI: [10.1016/j.burns.2009.06.091](https://doi.org/10.1016/j.burns.2009.06.091)]
- Schwartz JA, Goss SG, Facchin F, Avdagic E, Lantis JC. Surgical debridement alone does not adequately reduce planktonic bioburden in chronic lower extremity wounds. *J Wound Care* 2014; 23(9): s4-s8. [DOI: [10.12968/jowc.2014.23.Sup9.S4](https://doi.org/10.12968/jowc.2014.23.Sup9.S4)]
- Mosti G, Mattaliano V. The debridement of chronic leg ulcers by means of a new fluidjet-based device. *Wounds* 2006; 18(8): 227-237.
- Scholten SM, van den Bosch M, Niewenhuis M *et al.* Scar quality after surgical treatment of deep dermal burns with hydro-surgery compared to quarded knife, short and long-term outcome. *Poster Burns*: 37S: S18.
- Hong Ch-Ch, Nather A, Lee J, Mao H-T. Hydrosurgery is effective for debridement of diabetic foot wounds. *Ann Acad Med Singapore* 2014; 43: 395-399. [PMID: [25244988](https://pubmed.ncbi.nlm.nih.gov/25244988/)]
- Oosthuizen B, Mole T, Martin R, Myburgh J. Comparison of standard surgical debridement versus the VERSAJET Plus™ hydrosurgery system in the treatment of open tibia fractures: a prospective open label randomized controlled trial. *Int J Burn Trauma* 2014; 4(2): 53-58. PMID: [25356370](https://pubmed.ncbi.nlm.nih.gov/25356370/)
- Legemate CM, Goei H, Gostelie OFE, Nijhuis THJ, van Baar ME, van der Vlies CH; Dutch Burn Repository Group. Application of hydrosurgery for burn wound debridement: An 8-year cohort analysis. *Burns* 2019; 45(1): 88-96. DOI: [10.1016/j.burns.2018.08.015](https://doi.org/10.1016/j.burns.2018.08.015)